



## Round Ligament Varices Mimicking Inguinal Hernia in Pregnancy: Report of Two Cases

### Gebelikte İnguinal Herniyi Taklit Eden Round Ligament Varisleri: İki Vaka Sunumu

Samet GENEZ<sup>1</sup> [ID], Servan YAŞAR<sup>2</sup> [ID]

<sup>1</sup>Department of Radiology, Kocaeli Derince Education and Research Hospital, University of Health Sciences, Kocaeli, Turkey.

<sup>2</sup>Department of Radiology, Sancaktepe Şehit Profesör İlhan Varank Education and Research Hospital, Istanbul, Turkey.

**Article Info:** Received: 11.03.2021. Accepted: 16.03.2021.

**Correspondence:** Samet Genez; MD., Department of Radiology, Kocaeli Derince Education and Research Hospital, University of Health Sciences, Kocaeli, Turkey. E-mail: [sametgenez@hotmail.com](mailto:sametgenez@hotmail.com)

#### Abstract

Round ligament varices are a rare condition that usually occurs during pregnancy. Clinical findings are very similar to inguinal hernia. Patients usually present with groin pain and groin swelling that can be enlarged by the Valsalva maneuver. Since management is different, it is important to make a differential diagnosis of these two diseases.

**Keywords:** Round ligament, Varicose veins, Inguinal hernia.

#### Özet

Round ligament varisleri, gebelikte nadir görülen bir sağlık sorunu olup klinik bulgular kasık fıtığı ile oldukça benzerlik göstermektedir. Hastalar genellikle kasık ağrısı ve Valsalva manevrası ile büyüyen kasık şişliği şikayetiyle başvurmaktadır. Klinik yönetimi inguinal herniden farklı olduğu için bu iki hastalığın ayırıcı tanısının yapılması önemlidir.

**Anahtar Kelimeler:** Round ligament, Variköz venler, İnguinal herni.

#### Introduction

Round ligament varices (RLV) are a rare condition in a pregnant patient that is usually presented by inguinal swelling and pain [1]. Its clinical findings are very similar to inguinal hernia [2]. It is important to make a differential diagnosis of these two diseases to avoid unnecessary surgical treatment [1,2]. Color Doppler ultrasonography is the best method to view the tortuous venous structures of the round ligament compared to intestinal or omental contents indicating a hernia [3].

#### Case 1

A 29-year-old woman applied to the general surgery department with the complaint of bilateral groin swelling. The patient was referred to our radiology clinic for ultrasound (US) examination with the preliminary diagnosis of inguinal hernia. Physical examination revealed bilateral inguinal swelling enlarging with the standing position. On the gray-scale US, there were multiple, anechoic, tubular structures extending from the bilateral inguinal canal to the pelvic abdominal region. Color Doppler US confirmed hypervascularity and

venous flow which became more prominent during the Valsalva maneuver (Figure 1A). There were bilateral varicose veins in the lower extremities that started at the same time as the inguinal swelling. The patient indicated that she had similar complaints in her previous pregnancy and these findings resolved after delivery.

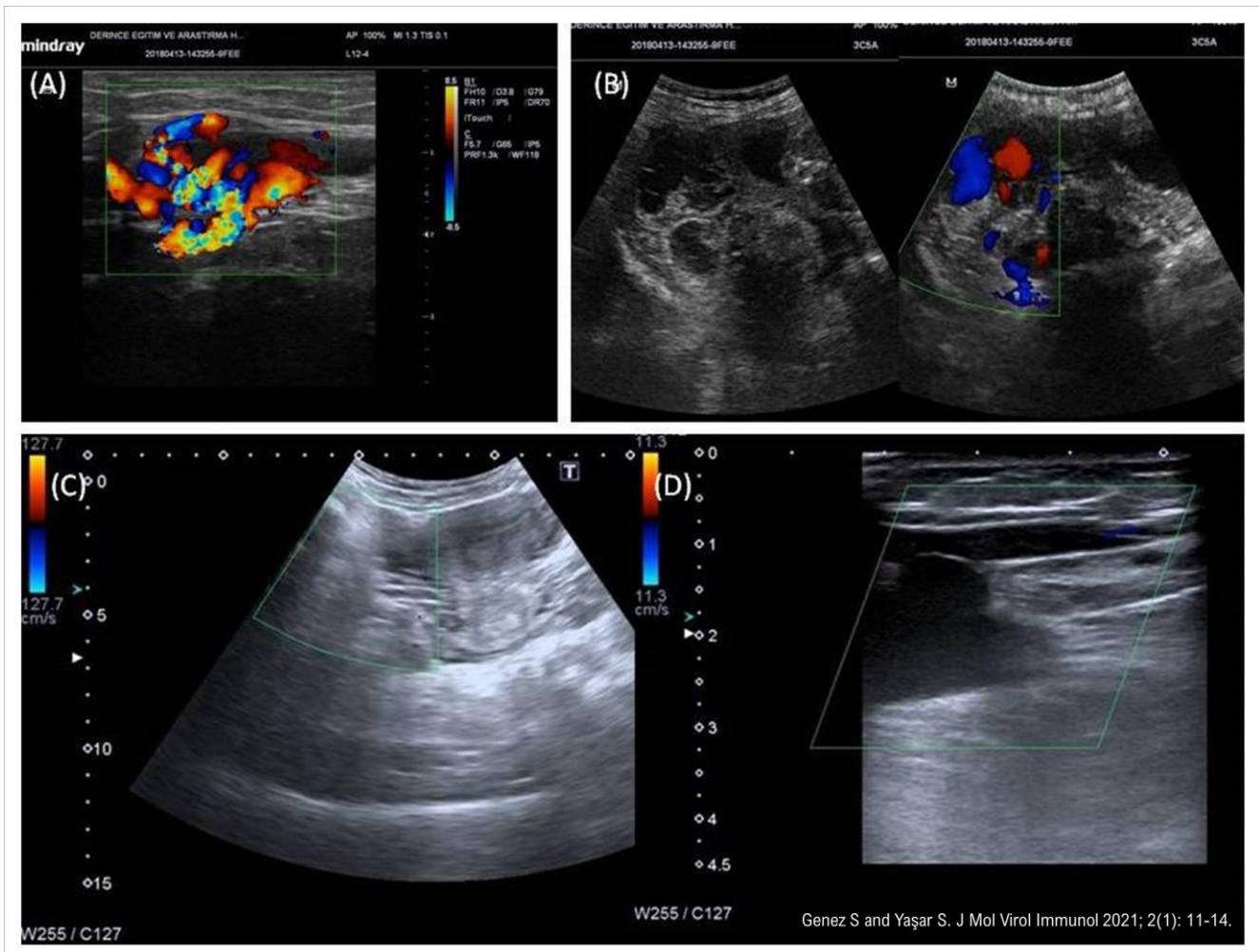
## Case 2

A 36-year-old woman, third gravida, complained of bilateral inguinal pain and swelling that started in the first trimester of pregnancy. Although there were no similar complaints in her first pregnancy, she had the same complaints in her second pregnancy and regressed completely after the birth. The patient also had bilateral lower

extremity varicose veins which started simultaneously with groin swelling that did not occur in previous pregnancies. On the gray scale and color doppler US, dilated, serpentine, varicose veins extending from the inguinal region to the parauterine area were observed (Figure 1B). She also had varicose veins with reflux flow through the bilateral great saphenous vein trace.

## Control Imaging of Both Patients After Delivery

Both patients were invited to our clinic for ultrasound evaluation approximately 6 months after their delivery. Varicose veins of the inguinal region, pelvic region, and lower extremities were completely disappeared in both patients (Figure 1C, D).



**Figure 1.** (A) Color doppler sonogram showing anechoic tubular structures in the inguinal canal and multiple dilated veins with a blood flow. (B) Gray scale and color doppler ultrasound images demonstrating dilated varicose veins extending to the parauterine area. (C-D) The control examination performed 6 months after delivery shows that the varicose veins of the inguinal and parauterine regions completely disappeared.

## Discussion

The round ligament originates at the uterine horns, exits the pelvis via the deep inguinal ring and passes through the inguinal canal, and terminates at the labia majora [4]. RLV arise from the veins draining the round ligament and the inguinal canal into the inferior epigastric vein [4].

Inguinal hernia is not a common reason of groin swelling in pregnancy. It was seen that pre-existing hernias before pregnancy were also regressed because expanding uterus pushes intestinal segments away from the inguinal canal [1]. In pregnant patients with inguinal swelling; the incidence of RLV is higher than the incidence of inguinal hernia [2]. The differential diagnosis of inguinal swelling other than RLVs and inguinal hernia includes endometriosis, lymphadenopathy, subcutaneous lipoma, cyst of the canal of Nuck, and mesothelial cyst [3]. The etiology of RLV in pregnancy is multifactorial. It is thought that smooth muscle relaxation in the veins due to increased progesterone, increased venous return and venous compression by the gravid uterus cause the formation of varicose veins [5].

Although the RLV is usually unilateral, approximately one-third of the cases in the literature are reported to be bilateral [2]. In our cases, the symptoms were bilateral and both patients had simultaneously varicose veins of lower extremities which started in pregnancy and resolved after delivery. In a literature review including 26 patients, it was observed that most

of the patients were pregnant and these patients were treated conservatively except one [4].

It is hard to distinguish RLV from inguinal hernia by clinical examinations since both have similar findings [6]. Pain, tenderness, and swelling are the most common symptoms, and both may enlarge with Valsalva maneuver and on standing position. For this reason, ultrasound examination is very important to make a differential diagnosis. Sonographic finding of RLV is the "bag of worms" appearance of subcutaneous tissue formed by multiple dilated veins and extends along the inguinal canal. In color Doppler imaging, the presence of venous flow that becomes more prominent during the Valsalva maneuver confirms the diagnosis [6,7].

The treatment of RLV is conservative, however, RLV require close observation during pregnancy because rupture of the varices and acute variceal thrombosis have been reported [8]. RLV are not a contraindication for vaginal delivery and the symptoms are expected to resolve in the early postpartum period.

## Conclusion

In a pregnant patient with groin swelling and pain, the physical examination is usually not sufficient for the final diagnosis, since inguinal hernia and RLV have similar findings. US and color doppler US examinations are recommended in all cases to avoid unnecessary surgery and to determine extension and complications of RLV.

**Consent for publication:** Informed consent was obtained for these two case reports. **Conflict of interest:** The authors declare that there is no conflict of interest. The authors alone are responsible for the content and writing of the paper. **Financial disclosure:** There is no financial support to this study.

## References

1. Tomkinson JS, Winterton WR. Varicoceles of the round ligament in pregnancy, simulating inguinal herniae. *Br Med J* 1955; 1(4918): 889-90. [[Crossref](#)]
2. Lechner M, Fortelny R, Ofner D, Mayer F. Suspected inguinal hernias in pregnancy--handle with care! *Hernia* 2014; 18(3): 375-9. [[Crossref](#)]
3. Lee DK, Bae SW, Moon H, Kim YK. Round ligament varicosities mimicking inguinal hernia in pregnancy. *J Korean Surg Soc* 2011; 80: 437-9. [[Crossref](#)]
4. Ryu KH, Yoon JH. Ultrasonographic diagnosis of round ligament varicosities mimicking inguinal hernia: Report of two cases with literature review. *Ultrasonography* 2014; 33(3): 216-21. [[Crossref](#)]
5. Cheng D, Lam H, Lam C. Round ligament varices in pregnancy mimicking inguinal hernia: an ultrasound diagnosis. *Ultrasound Obstet Gynecol* 1997; 9(3): 198-9. [[Crossref](#)]
6. Erok B, Öner EE, Yıldız H, Yılmaz E. Round Ligament Varicosities in Pregnancy. *J Acad Res Med* 2016; 6(2): 115-6. [[Crossref](#)]

**7.** Naik SS, Balasubramanian P. Round ligament varices mimicking inguinal hernia during pregnancy. Radiol Case Rep 2019; 14(8): 1036-8. [[Crossref](#)]

**8.** Chi C, Taylor A, Munjuluri N, Abdul-Kadir RA. Diagnostic dilemma: round ligament varicosities in pregnancy. Acta Obstet Gynecol Scand 2005; 84: 1126-7. [[Crossref](#)]