



A Prospective Study in Mogadishu, Somalia: Adenovirus, Herpesvirus, and Measles-related Ocular Infections and Complications

Somali Mogadişu'dan Prospektif Bir Çalışma: Adenovirus, Herpesvirus ve Kızamık İlişkili Göz Enfeksiyonları ve Komplikasyonlar

Mustafa KALAYCI¹ [ID], Ibrahim ABDI KEINAN¹ [ID], Fatih ŞAHİNER² [ID]

¹Department of Ophthalmology, Mogadishu Somalia-Türkiye Recep Tayyip Erdoğan Training and Research Hospital, Mogadishu, Somalia.

²Department of Medical Microbiology, Mogadishu Somalia-Türkiye Recep Tayyip Erdoğan Training and Research Hospital, Mogadishu, Somalia.

Article Info: Received; 11.05.2022. Accepted; 25.07.2022. Published; 28.07.2022.

Correspondence: Mustafa Kalaycı; Assoc.Prof.; Department of Ophthalmology, Antalya Training and Research Hospital, University of Health Sciences, Antalya, Türkiye. E-mail: drkalayci07@hotmail.com

Abstract

The aim of this study is to examine the incidence, clinical and epidemiological characteristics of ocular viral infections in consecutive patients admitted to the ophthalmology outpatient clinic of a tertiary education and research hospital located in Mogadishu-Somali. In the study, it was aimed to reach data that could be specific for the country and city where the study was conducted by examining patients in different age and gender groups with findings compatible with viral infections in their clinical examinations in terms of risk factors and complications. The study was conducted as a four-month (December 2019-March 2020) prospective follow-up study and included the analysis of data from 63 patients. Eight (12.7%) of the patients were affected bilaterally by infection and related complications, and 55 patients were affected in one eye (25 left eyes and 30 right). In this study based on clinical examination results, the frequency of viral eye infections was found as adenovirus 66.7% (42/63), herpes simplex virus 27.0% (17/63), herpes zoster virus 4.76% (3/63), and measles virus 1.59% (1/63), respectively. HIV (human immunodeficiency virus) serology was negative for all patients. The most common complications were as follows; keratitis 87.3% (55/63), conjunctivitis 84.1% (53/63), anterior uveitis 15.9% (10/63) and glaucoma 17.5% (11/63). Anterior uveitis, cataract, synechia and glaucoma occurrence rates were found to be significantly higher in patients with hypertension and/or diabetes mellitus ($p < 0.05$). While 28 of the patients (44.4%) could not provide any information on the place of transmission where the infection was acquired, the most frequently reported possible transmission sites were 23 homes (36.5%) and 10 workplaces (15.9%). It was determined that adenovirus infections affect a wide age group (9-60 years; mean: 28.0 ± 10.7), herpes simplex virus infections affected young and middle-aged individuals (16-52 years; mean: 31.3 ± 11.36 years) and herpes zoster virus infections affected older age groups (45-69 years; mean: 56.3 ± 12). Our study data show that reducing the burden of viral eye infections and related complications in Mogadishu, Somali population living in crowded families and in conditions with lack of infrastructure depends on many parameters such as access to health services, early treatment, control of chronic diseases and public health awareness, and viral eye infections and it shows that the burden of related complications can be possible with the development of socio-economic and general public health conditions together.

Keywords: Somalia, Viral infection, Eye, Complication, Keratitis, Conjunctivitis, Uveitis, Glaucoma.

Özet

Bu çalışmanın amacı, Mogadişu-Somali'de yerleşik bir üçüncü basamak eğitim ve araştırma hastanesi göz hastalıkları polikliniğine başvuran ardışık hastalarda oküler viral enfeksiyonlarının görülme sıklığını, klinik ve epidemiyolojik özelliklerini incelemektir. Çalışmada farklı yaş ve cinsiyet gruplarında yer alan ve klinik muayenelerinde viral enfeksiyonlarla uyumlu bulguları olan hastalar risk faktörleri ve komplikasyonlar yönünden incelenerek çalışmanın yapıldığı ülke ve şehir için özgün olabilecek verilere ulaşılması hedeflenmiştir. Çalışma dört aylık (Aralık 2019-Mart 2020) prospektif bir izlem çalışması olarak yürütülmüş olup 63 hastadan elde edilen verilerin analizini içermektedir. Hastaların 8'i (%12.7) enfeksiyon ve ilişkili komplikasyonlardan bilateral, 55 hasta ise tek gözünden (25 sol göz ve 30 sağ) etkilenmişti. Klinik muayene sonuçlarını baz alan bu çalışmada viral göz enfeksiyonlarının görülme sıklığı sırasıyla adenovirus %66.7 (42/63), herpes simpleks virus %27.0 (17/63), herpes zoster virus %4.76 (3/63) ve kızamık virusu enfeksiyonu %1.59 (1/63) olarak bulundu. Hastaların tümü için HIV (human immunodeficiency virus) serolojisi negatif idi. En sık gelişen komplikasyonlar; keratit %87.3 (55/63), konjunktivit %84.1 (53/63), anterior üveit %15.9 (10/63) ve glokom %17.5 (11/63) olarak saptandı. Hipertansiyon ve/veya diabetes mellitusu olan hastalarda anterior üveit, katarakt, sineşi ve glokom gelişme oranları anlamlı derecede yüksek bulundu ($p<0.05$). Hastaların 28'i (%44.4) enfeksiyonun edinildiği bulaş yeri hakkında bir bilgi sunamazken, en sık bildirilen muhtemel bulaş yerleri 23 ev (%36.5) ve 10 işyeri (%15.9) şeklinde idi. Adenovirus enfeksiyonları geniş bir yaş grubunu etkilerken (9-60 yaş; ortalama: 28.0 ± 10.7), herpes simpleks virus enfeksiyonlarının genç ve orta yaşlı bireyleri (16-52 yaş; ortalama: 31.3 ± 11.36) ve herpes zoster virus enfeksiyonlarının daha ileri yaş grubunu (45-69 yaş; ortalama: 56.3 ± 12) etkilediği belirlendi. Çalışma verilerimiz kalabalık aileler halinde ve altyapı imkanlarının eksik olduğu koşullarda yaşayan Mogadishu, Somali popülasyonunda viral göz enfeksiyonları ve ilişkili komplikasyonların getirdiği yükü azaltmanın sağlık hizmetlerine erişim, erken tedavi, kronik hastalıkların kontrolü ve toplum sağlığı farkındalığının geliştirilmesi gibi birçok parametreye bağlı olduğunu ve viral göz enfeksiyonları ve ilişkili komplikasyonların getirdiği yükün sosyo-ekonomik ve genel halk sağlık koşullarının birlikte geliştirilmesi ile mümkün olabileceğini göstermektedir.

Anahtar Kelimeler: Somali, Viral enfeksiyon, Göz, Komplikasyon, Keratit, Konjunktivit, Üveit, Glokom.

Introduction

Bacterial, fungal, viral and parasitic agents and polymicrobial agents, which include different types of microorganisms, can cause eye infections [1-3]. While eye infections can develop by direct contact and inoculation with the infectious agent, or by reaching the eye through blood and nerves; in infections, any tissue of the eyeball, orbit, and ocular adnexa can be affected and in some infections serious complications such as vision loss may develop [4-6].

In "herpes simplex ophthalmicus" infections, which are mainly caused by neurotropic herpes simplex virus type 1 (HSV-1) and less frequently by HSV-2, can be affect all structures of the eye including the eyelids (*blepharitis*), conjunctiva (*conjunctivitis*), cornea (*keratitis*), uvea (*uveitis*), and rarely retina (*retinitis*) [5]. Severe secondary HSV infections associated with post-latent viral reactivation are associated with complications that can cause serious visual disturbances in all these structures [5].

Human adenovirus (HAdV) strains are an important cause of viral conjunctivitis and are responsible for 15% to 70% of all conjunctivitis cases in the world [2]. Infectious keratitis involving the corneal layers is a major cause of ocular morbidity worldwide and is the most common cause of unilateral corneal blindness in low-resource settings [3]. The population incidence of infectious keratitis in these settings is estimated at 800 cases per 100,000 people per year, approximately 70 times higher than in high-source settings [3]. The clinical picture and etiology of infectious keratitis vary geographically, as it depends on both environmental and host factors. It has been shown that the most common microorganisms causing corneal infections are bacteria and fungi [1]. Viral infections and acanthamoeba keratitis are less common, but these agents are among the important causes of corneal blindness in developed countries [1].

Data on the epidemiological features of HSV-1, HSV-2 and herpes zoster virus strains and other

viral eye infections, which are well known to cause recurrent and devastating keratitis in Western countries, are still insufficient for Somalia, as in many sub-Saharan African countries [3]. The primary objective of this prospective follow-up study is to reveal the prevalence of viral eye infections and complications in the population and patient profiles, thus contributing to the planning of preventive measures and studies of healthcare professionals and policy makers for the prevention of permanent damage associated with viral eye infections.

Material and Method

Study population and design

This hospital-based prospective study was conducted after obtaining approval from the institutional ethics committee (Ethics Committee of Somalia Turkey Recep Tayyip Erdogan Education and Research Hospital, date: 05.12.2019, decision no: 193, number: MSTH/2734). Written and verbal consent was obtained from all study subjects or their parents. All patient's information was protected with confidentiality, and the study was conducted in accordance with the Declaration of Helsinki.

In the study, the examination and follow-up results of consecutive patients who applied to the eye diseases unit in the 4-month period between December 2019 and March 2020 and had ocular findings and epidemiological histories compatible with viral infections were recorded and analyzed prospectively. The study recorded patients' usual follow-up visits, and the study design was not an intervention or an experimental study.

Clinical examinations and tests

All patients underwent a complete ophthalmic examination. Anterior segment examinations were performed with a slit lamp biomicroscope (Righton MW50D, Tokyo, Japan). Detailed dilated fundus examinations, optical coherence tomography, ocular ultrasonography, laboratory tests such as fasting blood glucose, hemoglobin A 1c, and radiological imaging were performed when necessary. Intraocular pressure (IOP) was measured in all patients by the same investigator using the same Goldmann applanation tonometer (Haag-Streit, Switzerland) under a slit lamp

microscope, and at least three measurements were averaged.

HIV (human immunodeficiency virus) serological tests were performed on the Architect I 2000 SR (Abbott Diagnostics, USA) system using the Architect HIV Ag/Ab Combo Reagent Kit (Abbott Diagnostics, Germany). Results were considered S/Co ≥ 1.00 reactive and S/Co < 1.00 non-reactive.

Inclusion and exclusion criteria

Infections were classified on the basis of clinical history (such as unilateral painful skin rash in the dermatomal distribution of the trigeminal nerve as a sign of herpes zoster virus infection), disease characteristics (such as typical herpetic findings), laboratory results, and response to treatment initiated according to current diagnostic criteria. Routine control examinations were performed at clinical follow-up visits, and post-treatment changes were evaluated. During the study period, patients who had repeated outpatient visits and continued treatment and follow-up were considered as a single patient. Patients with a history of seasonal allergic conjunctivitis, contact lens wear, recent ocular surgery or trauma, history of chronic ocular disease, iodine allergy, any bleeding disorder, dry eye according to slit lamp examination, and purulent ocular discharge were excluded from the study.

Statistical analyzes

At the end of the study, basic statistical data such as frequency, mean, \pm standard deviation were obtained, comparisons were made by using commonly used statistical calculations such as Chi-square Test and Fisher Exact Probability Test. A p value < 0.05 was considered statistically significant (at the 95% confidence interval). All analyses were performed using SPSS v. 22.0 (IBM SPSS Statistics Version 22.0., IBM Corp., Armonk, NY).

Results

A total of 63 patients aged between 2-69 (mean 29.8 ± 12.8) were included in the study. Based on clinical examination results, viral eye infections are in order of frequency; adenovirus 66.7% (42/63), herpes simplex virus 27.0%

(17/63), herpes zoster virus 4.76% (3/63) and measles virus 1.59% (1/63) was defined as. The incidence of anterior uveitis, cataract, synechia, and glaucoma, which are complications associated with eye infections, was found to be statistically significantly higher in patients with diabetes mellitus and/or hypertension than in patients without (Table 1). There was no significant difference in the incidence of keratitis, conjunctivitis, and retinitis between patients with

and without diabetes mellitus and/or hypertension. No relationship was found between gender and infection complications.

While there was no follow-up history of adenovirus infections, defined as acute infections, patients infected with herpes simplex virus, herpes zoster virus, and measles also included patients with a long history of infection or those followed up for recurrent infections and long-term complications.

Table 1. The incidence of complications in the presence of possible risk factors for viral eye infections.

Disease		Keratitis		Conjunctivitis		Anterior uveitis		Cataract		Synechiae		Retinitis		Glaucoma	
		yes	no	yes	no	yes	no	yes	no	yes	no	yes	no	yes	no
Diabetes mellitus	yes	7	1	8	0	6	2	5	3	4	4	1	7	5	3
	no	48	7	45	10	4	51	4	51	0	55	1	54	6	49
<i>p value</i>		0.7336		0.2289		< 0.0001		< 0.0001		< 0.0001		0.2396		0.0028	
Hypertension	yes	6	1	6	1	5	2	4	3	4	3	1	6	5	2
	no	49	7	47	9	5	51	5	51	0	56	1	55	6	50
<i>p value</i>		0.6332		0.6935		0.0006		0.0060		< 0.0001		0.2115		0.0012	
DM + HT	yes	5	1	6	0	5	1	4	2	4	2	1	5	4	2
	no	50	7	47	10	5	52	5	52	0	57	1	56	7	50
<i>p value</i>		0.5733		0.3379		0.0002		0.0028		< 0.0001		0.1828		0.0068	
Gender	M	28	5	29	4	5	28	4	29	3	30	2	31	6	27
	F	27	3	24	6	5	25	5	25	1	29	0	30	5	25
<i>p value</i>		0.4099		0.3051		0.5698		0.4374		0.3435		0.2704		0.5700	
All cases (n=63)		55	8	53	10	10	53	9	54	4	59	2	61	11	52

HT; Hypertension. DM; Diabetes mellitus. F; Female. M; Male.

Table 2. Epidemiological data in viral infections.

Virus	Number of cases	Possible contamination site	Onset of infection (how many days)	HIV	Diabetes mellitus	HT	Gender	The average age (age range)
Adenovirus	42	19 unknown (%45.2) 14 home (%33.3) 8 work (%19) 1 school (%2.4)	14-17 (avg.: 7.17)	N	3	2	23: M 19: F	28.0±10.7 (9-60)
Herpes simpleks virus	17	6 unknown (%35.3) 8 home (%47.1) 2 work (%11.8) 1 travel (%5.9)	1-23* (avg.: 8.7)	N	3	3	9: M 8: F	31.3±11.36 (16-52)
Herpes zoster virus	3	3 unknown (%100)	10-27* (avg.: 17.3)	N	2	2	2: F 1: M	56.3±12 (45-69)
Measles virus	1	1 home (%100)	long period	N	-	-	1: F	2
Total:	63	28 unknown (%44.4) 23 home (%36.5) 10 work (%15.9) 1 school (%1.6) 1 travel (%1.6)	1-27 (avg.: 8.08)	N	8	7	33: M 30: F	29.8±12.8 (2-69)

*Duration of acute infection. avg.: average. HIV; Human immunodeficiency virus. HT; Hypertension. N; Negative. F; Female. M; Male.

Table 3. Findings and complications in viral eye infections.

Virus	Case (n)	Affected eye	Keratitis	Conjunctivitis	A. uveitis	Cataract	Synechia	Retinitis	Glaucoma
Adenovirus	42	18 R - 20 L 4 bilateral	35	37	3	2	0	0	6 (23-25 mmHg)
Herpes simplex virus	17	12 R - 3 L 2 bilateral	17	14	4	3	2	2	3 (24-28 mmHg)
Herpes zoster virus	3	2 L 1 bilateral	3	2	3	3	2	0	2 (26-28 mmHg)
Measles virus*	1	1 bilateral	0	0	0	1	0	0	could not be evaluated
Total:	63	30 R - 25 L 8 bilateral	55 (87.3%)	53 (84.1%)	10 (15.9%)	9 (14.3%)	4 (6.3%)	2 (3.2%)	11 (17.5%)

*Bilateral intraocular pressure 34 mmHg and vascularized corneal leukoma. L; left. R; right. A; anterior (uveitis)

Table 4. Frequency of co-existence of complications associated with viral eye infections.

Disease	Keratitis		Conjunctivitis		A. uveitis		Cataract		Synechia		Retinitis		Glaucoma	
	yes	no	yes	no	yes	no	yes	no	yes	no	yes	no	yes	no
Keratitis (n=55)			47*	8	10	45	8	47	4	51	2	53	9	46
Conjunctivitis (n=53)	47*	6			9	44	7	46	4	49	2	51	9	44
Anterior uveitis (n=10)	10	0	9	1			7	3	4	6	1	9	5	5
Cataract (n=9)	8	1	7	2	7	2			4	5	2	7	5	4
Synechia (n=4)	4	0	4	0	4	0	4	0			1	3	4	0
Retinitis (n=2)	2	0	2	0	1	1	2	0	1	1			1	1
Glaucoma (n=11)	9	2	9	2	5	6	5	6	4	7	1	10		

*The rate of keratoconjunctivitis in all patients (n=63) was 74.6% (47/63). A; anterior (uveitis).

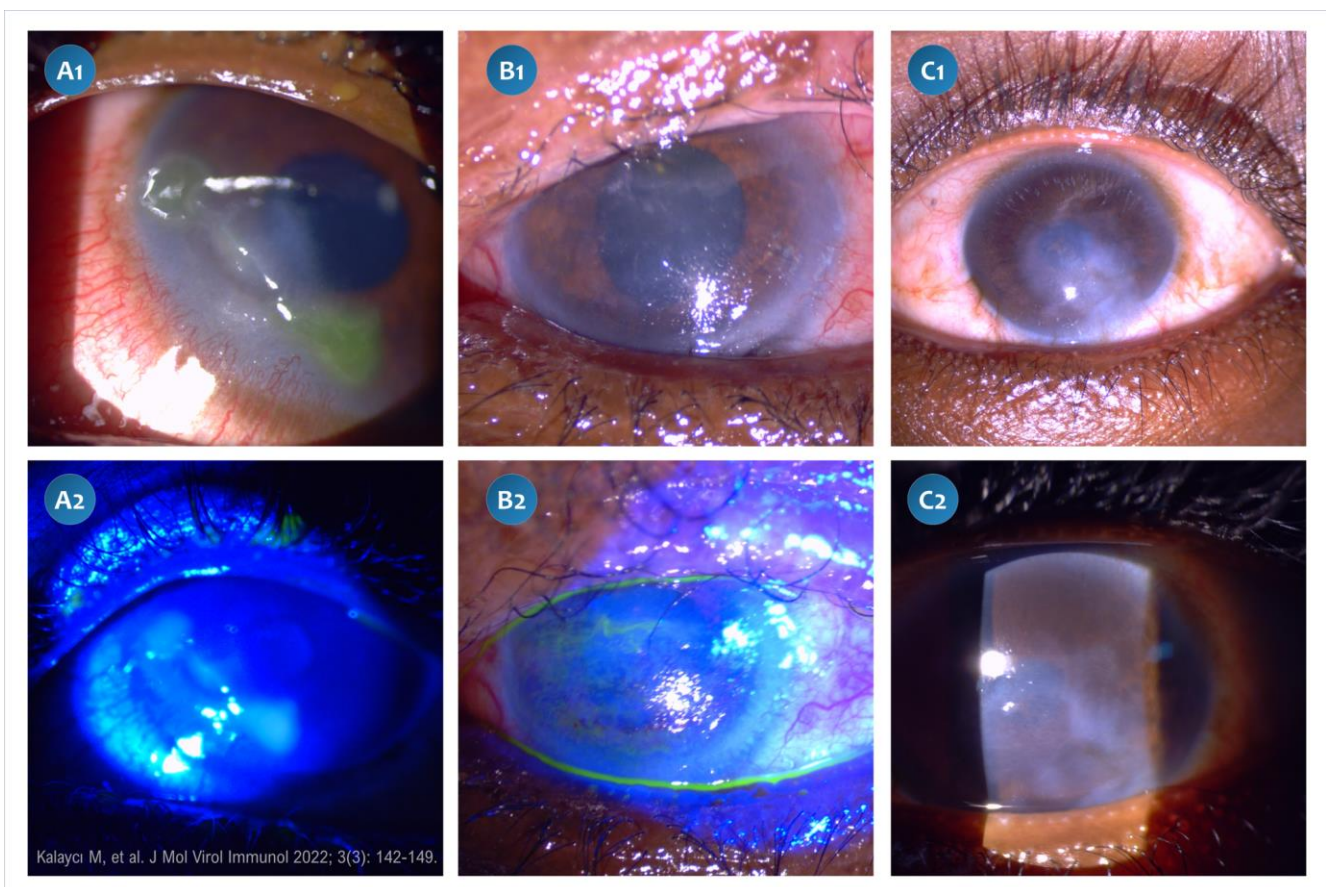


Figure 1. (A1, A2) The appearance of dendritic ulcer in the cornea of a patient with herpes simplex virus infection. (B1, B2): The presence of corneal epithelial surface irregularity and microedema during the healing phase in a patient with herpes zoster virus infection. (C1, C2) Complicated corneal scarring associated with untreated HSV infection.

Discussion

Early intervention in viral eye infections is important in preventing possible complications and negative consequences. For example, with early and accurate diagnosis in herpetic anterior uveitis, it is possible to prevent complications that may cause vision loss such as keratitis, glaucoma, and cataracts, by reducing re-infections. Infectious microorganisms can be identified at the species level by examining eye samples using molecular methods. However, due to limiting reasons such as the availability and high cost of tests in low-resource settings, the patient's medical history and detailed examinations of characteristic clinical findings are important in the diagnosis, treatment, and follow-up of viral eye infections [7].

In our study, the most common complications associated with viral eye infections were keratitis 87.3%, conjunctivitis 84.1%, anterior uveitis 15.9% and glaucoma 17.5% (Table 3). Also, the majority of patients with anterior uveitis, cataract, synechia, retinitis and glaucoma (100%, 88.9%, 100%, 100%, 81.8%, respectively) had keratitis accompanying the disease picture (Table 4). In a study carried out the ophthalmology outpatient clinic of three hospitals in rural South Africa, it has been reported that 21 (45.7%) keratitis cases determined in patients (n=46) presenting with symptoms of infectious keratitis were complicated with anterior uveitis, and 18 (86%) of these were HIV-infected viral keratitis cases [3]. In the same study, it was stated that HIV-infected individuals are especially at higher risk for herpes zoster keratitis, and the high HIV prevalence in this region may play an important role in the distribution of keratitis-related pathogens [3]. In that study, VZV (varicella zoster virus)-DNA was detected in 11 (24%) corneal swabs and HSV-1 DNA was detected in 5 (11%) samples. In our study, 17 (30.9%) of 55 keratitis cases were HSV-related, while herpes zoster-associated keratitis was found in 3 (5.45%) cases. We can say that the most important reason for this difference is related to the very low prevalence of HIV infection in the Somali population [8], and all the cases included in our study were negative in terms of anti-HIV serology. In our study population, complications such as anterior uveitis, cataract,

synechia and glaucoma associated with viral eye infections were found to be significantly higher in patients with chronic diseases such as hypertension and/or diabetes mellitus ($p < 0.05$). In the aforementioned study, 31 (67.4%) cases of keratitis were associated with bacterial infections (14 with viral keratitis, 17 with only bacterial), while no adenovirus was detected in corneal swab samples (by real time PCR), in our study that did not include bacterial infections, viral keratitis was the most common. We found that the most common cause (63.5%, 35/55) was adenovirus infection [3].

In our study, most of the patients (85.5%; 47/55) with keratitis were also accompanied by conjunctivitis. While conjunctivitis was detected in 84.1% (53/63) of all patients, the most common causes of viral conjunctivitis were adenovirus 69.8% (37/53) and herpes simplex virus 26.4% (14/53) (Table 3). The diagnosis of viral conjunctivitis manifested by conjunctival hyperemia is generally made based on clinical features. Confirmation of the diagnosis in the laboratory also is important because it can help physicians to take appropriate hygienic measures quickly and determine the epidemiological significance of the infection [2]. A complication of viral conjunctivitis is the presence of multifocal subepithelial corneal infiltrates, which are focal lesions that may represent a cellular immune reaction against viral antigens deposited in the corneal stroma under Bowman's membrane. These subepithelial infiltrates that occur in adenoviral conjunctivitis can last for weeks or years and may cause visual impairment if the infiltrate area includes the visual axis [2]. Therefore, close monitoring and early treatment, if necessary, are important to reduce the risk of permanent visual impairment [2].

Viral anterior uveitis should be considered in the presence of anterior uveitis with high intraocular pressure, corneal involvement, and iris atrophic changes [9]. While the most common causes of viral anterior uveitis are HSV and VZV, anterior uveitis can also develop less frequently in different viral infections such as cytomegalovirus, rubella virus, human T-cell lymphotropic virus-type 1, HIV, Chikungunya virus, Zika virus, and Ebolavirus [9]. Herpetic anterior uveitis can be

presented with or without corneal involvement. In a study including 4.5 years of retrospective follow-up data in Turkey examining 67 unilateral anterior uveitis cases, it was reported that anterior uveitis was presented with corneal involvement in 42 eyes (62.6%), while without in 25 (37.3%) eyes [7]. In our study, keratitis was detected at the same time in all of the 10 anterior uveitis cases (these 4 associated with HSV, 3 VZV, and 3 adenovirus-) during the four-month follow-up period. Different complications were also observed in these cases, including conjunctivitis in 9, cataract in 7, and synechia in 4 of the patients (Table 4). We observed adenovirus-associated anterior uveitis in 3 cases in the present study, although anterior uveitis is a rarely reported condition in untreated complicated adenovirus infections [10].

In our study, the mean time to hospital admission (excluding measles with long-term complications) from the onset of infection was 8.1 days (1-27 days) (Table 2). We also observed that infections progress to permanent vision loss with multiple complications in cases with long hospital admissions (Figure 1). In particular, the high complication rates in cases with HT and DM reveal that deficiencies and inadequacies in the treatment of such chronic diseases which are common in the community as additional conditions that should be eliminated.

The most important limitation of the study is the inability to make confirmatory laboratory diagnosis for viral agents. At the time of the study, there was no infrastructure for polymerase chain reaction (PCR) tests in Somalia, even for viruses such as HIV, Hepatitis B and Hepatitis C, for which molecular diagnosis has become a routine laboratory test worldwide [8,11]. Other limitations are the inability to observe possible seasonal effects due to the small number of cases and the short follow-up period. Although similar seasonal characteristics are observed throughout the year in Somalia, it has been reported that changes in precipitation and drought may affect the incidence of parasitic infections [12].

Conclusion

As a result, in our study, it was determined that eye infections spread mainly as household transmission in Mogadishu and Somali population, living in crowded families and in conditions with insufficient infrastructure facilities, and high complication rates were observed, especially in patients with hypertension and diabetes mellitus, due to the limited access to treatment opportunities. It shows that reducing the burden of related complications depends on many parameters and can be possible by improving socio-economic and general public health conditions together and expanding access to treatment opportunities.

Conflict of interest: The authors declare that there is no conflict of interest. The authors alone are responsible for the content and writing of the paper. **Financial disclosure:** There is no financial support to this study.

References

1. Ting DSJ, Ho CS, Deshmukh R, Said DG, Dua HS. Infectious keratitis: an update on epidemiology, causative microorganisms, risk factors, and antimicrobial resistance. *Eye (Lond)* 2021; 35(4): 1084-101. [Crossref]
2. Pinto RD, Lira RP, Arieta CE, Castro RS, Bonon SH. The prevalence of adenoviral conjunctivitis at the Clinical Hospital of the State University of Campinas, Brazil. *Clinics (Sao Paulo)* 2015; 70(11): 748-50. [Crossref]
3. Schaftenaar E, Peters RP, Baarsma GS, Meenken C, Khosa NS, Getu S, et al. Clinical and corneal microbial profile of infectious keratitis in a high HIV prevalence setting in rural South Africa. *Eur J Clin Microbiol Infect Dis* 2016; 35(9): 1403-9 [Crossref]
4. Rumelt S. Overview of Common and Less Common Ocular Infections. In: Rumelt S (ed), *Advances in Common Eye Infections* [Internet]. 2016, IntechOpen, London. [Crossref]
5. Kanukollu VM, Patel BC. Herpes Simplex Ophthalmicus. In: *StatPearls* [Internet]. 2021, StatPearls Publishing. [PubMed]
6. Şahiner F, Siğ AK, Savaşçı Ü, Tekin K, Akay F. Zika Virus-associated Ocular and Neurologic Disorders: The Emergence of New Evidence. *Pediatr Infect Dis J* 2017; 36(12): e341-e346. [Crossref]
7. Kardeş E, Bozkurt K, Sezgin Akçay Bİ, Ünlü C, Aydoğan Gezginaslan T, Ergin A. Clinical Features and Prognosis of Herpetic Anterior Uveitis. *Turk J Ophthalmol* 2016; 46(3): 109-13. [Crossref]

- 8.** Şahiner F, Idiris MH, Hoşbul T, Adam AA, Osman MM, Sümbül HE, et al. HIV Seroprevalence in Mogadishu, Somalia: A Retrospective Study between 2015 and 2019. *Clin Lab* 2022; 68(7): 1347-54. [[Crossref](#)]
- 9.** Babu K, Konana VK, Ganesh SK, Patnaik G, Chan NSW, Chee SP, et al. Viral anterior uveitis. *Indian J Ophthalmol* 2020; 68(9): 1764-73. [[Crossref](#)]
- 10.** Meyer-Rüsenberg B, Loderstädt U, Richard G, Kaulfers PM, Gesser C. Epidemic keratoconjunctivitis: the current situation and recommendations for prevention and treatment. *Dtsch Arztebl Int* 2011; 108(27): 475-80. [[Crossref](#)]
- 11.** Ali Adam A, Şahiner F, Tanoğlu A, Hoşbul T, Hassan Kadle MA, Muse Osman M, Yüksel S, Sümbül HE, Ay N, Cebeci İ, Bashir AM, Bahçeci O. Seroprevalence and Genotype Distribution of Hepatitis C Virus in Mogadishu, Somalia: A Comprehensive Study. *J Mol Virol Immunol* 2021; 2(3): 115-22. [[Crossref](#)]
- 12.** Nur Adan F, Muse Osman M, Bashir AM, Aygar İS, Er S, Sarı O, Bahçeci O, Hoşbul T, Savaşçı Ü, Adam Moussa M, Şahiner F. Intestinal Parasites and HIV Co-infections in Mogadishu (Somalia): A Retrospective Evaluation of Four-Year Follow-up Data. *J Mol Virol Immunol* 2021; 2(4): 123-35. [[Crossref](#)]