



COVID-19 Pneumonia: Experiences Regarding the Use of Computed Tomography in Diagnosis and Follow-up

COVID-19 Pnömonisi: Tanı ve Takipte Bilgisayarlı Tomografi'nin Kullanımı ile İlgili Deneyimler

Mehmet TAHTABAŞI¹ [ID]

¹Department of Radiology, University of Health Sciences- Mehmet Akif Inan Education and Research Hospital, Sanliurfa, Turkey.

Article Info: Received: 14.09.2020. Accepted: 23.09.2020.

Correspondence: Mehmet Tahtabaşı; Asist.Prof., Department of Radiology, University of Health Sciences- Mehmet Akif Inan Education and Research Hospital, Sanliurfa, Turkey. E-mail: mehmettahtabasi@gmail.com

Dear Editor

The unknown pneumonia cases firstly reported in Wuhan city of China in December 2019, then disease was named coronavirus disease (COVID-19) and the causative virus was named as severe acute respiratory syndrome coronavirus 2 (SARS-CoV-2), and following it was declared by the World Health Organization (WHO) as a global public health emergency on January 30, 2020 [1-4]. Real-time reverse transcriptase polymerase chain reaction (rRT-PCR) is accepted as the gold standard for diagnosis, which is the most important step in the control and management of the outbreak. However, high false negativity rates may lead to delay in the isolation and medical treatments of suspected cases and increase the risk of transmission [5]. Therefore, computed tomography (CT) plays a very important role in the detection of viral pneumonia in clinically suspected cases, and high accuracy rates of CT have been reported by referring to rRT-PCR in studies [6]. If the patient has epidemiological history and clinical features in terms of viral pneumonia, even if the second rRT-PCR is negative, it should be accepted as positive for COVID-19 infection, considering the CT findings, and such patients should be evaluated

with follow-up CT for the course of COVID-19 pneumonia and the rRT-PCR test should be repeated for confirmation of diagnosis [6,7]. In the meantime, clinically diagnosed cases should be isolated and treated to reduce the risk of transmission. CT can be considered as a useful test in situations where rapid decision is required due to delayed results, lack of kit and false negative test results.

CT imaging features of COVID-19 pneumonia

In most of the studies, COVID-19 typically occurs with ground glass opacity (GGO) with peripheral, posterior, diffuse or lower zone distribution and GGO has been shown to be alone or together with consolidation [8-11]. It has also been reported that GGO often has a rounded morphology or shows a "Crazy paving" pattern [8,10]. However, the majority of cases have opacities with no clear or specific distribution, and the dominant perihilar pattern has not been reported [10]. Bronchial wall thickening, mucus plugs, nodules (tree-in bud and centrilobular), which are common in infections, are not typical in this disease [10]. Lymphadenopathy and pleural effusion have been reported rarely [8,12].

The frequency of imaging findings is also related to when infected patients are imaged. A

small majority of patients may have a negative CT in the first 2 days from the onset of symptoms, and GGO usually occurs 0-4 days after symptom onset and peaks at 6-13 days. [10,11,13]. For this reason and according to our observations; being negative in CT, especially in early disease, may not be enough to rule out the possibility of COVID-

19 and the frequency of consolidation increases in the later stages of the disease course [Figure 1,2]. In addition, the frequency of the "reversed halo" sign, which is not typically found near the onset of the disease, also increases in the following periods [10].

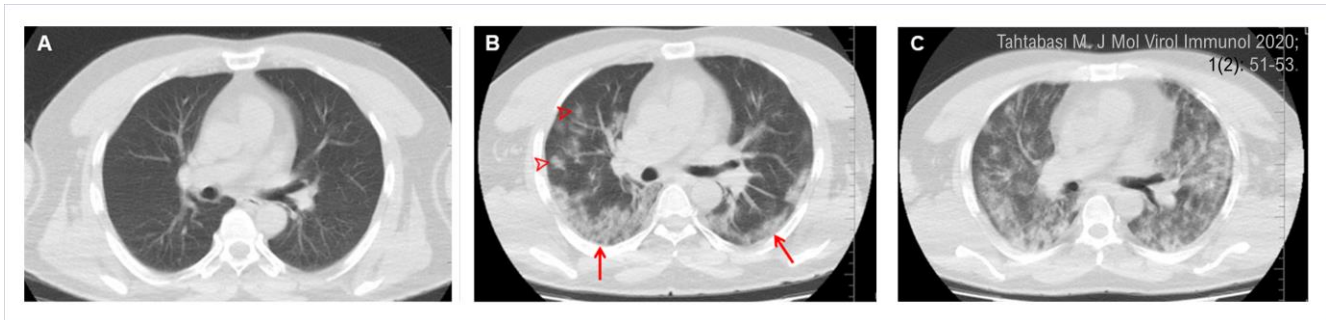


Figure 1. Initial and follow-up computed tomography (CT) images of a 48-year-old male patient with positive rRT-PCR. A) Initial CT (day one) shows that the lung is normal. B) CT on the fifth day showing patchy ground glass opacities (*arrowheads*) and Crazy paving pattern (*arrows*) posteriorly. C) CT on day 19 shows that the lesions have progressed, and acute respiratory distress syndrome has developed (at this stage, the patient is treated in the intensive care unit).

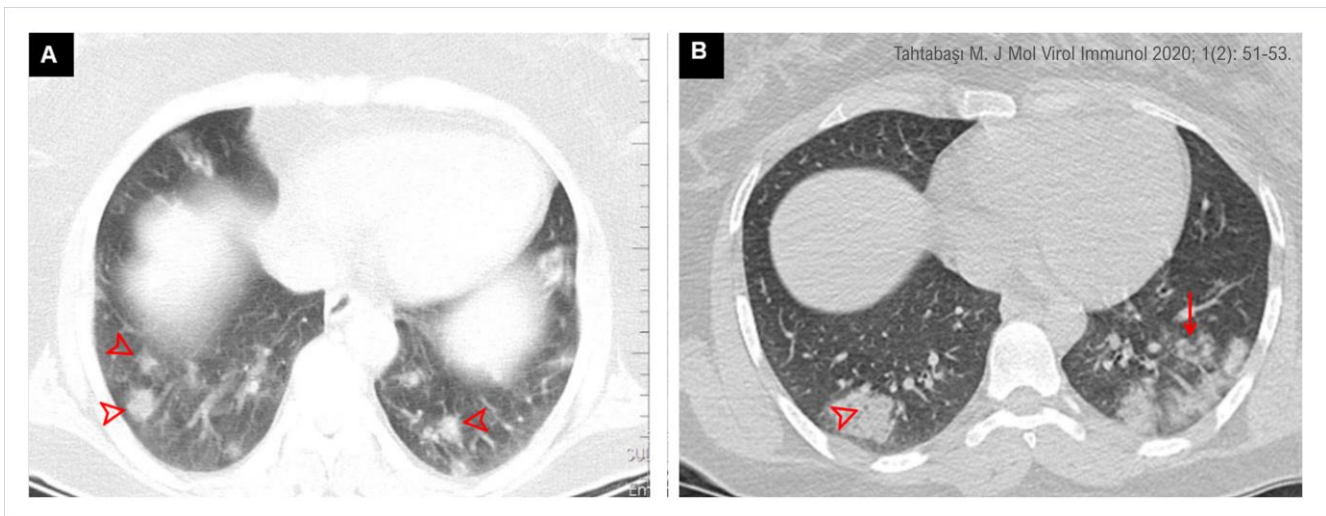


Figure 2. Chest CT images of two different patients with positive rRT-PCR test in the lung window. A) CT images show multiple ground glass opacities (*arrowheads*) located in the lower lung lobes and periphery of both lungs. B) CT images of a different patient show ground glass opacities and patchy consolidations (*arrow*) in the lower lobes and periphery of the lung. Pay attention to the air bubble sign (*arrowhead*) within the lesion.

Follow-up CT indications, ranges and dosage for patients with COVID-19

We have experienced that one of the characteristic features of COVID-19 pneumonia is its rapid progression, and the best method to evaluate the progression of the disease is radiological imaging. Chest X-ray is recommended in severe and critical cases followed up in

intensive care because of its ability to make bed head and portability. CT is the best method to show lesions and follow-up due to its high resolution. Follow-up intervals may vary from one day to 14 days depending on the progression of lung lesions and the development of acute respiratory distress syndrome (ARDS) or the resolution of regression. CT protocols have been

reported in two types, normal and low dose. Normal dose CT is recommended because round and small GGO, which are early imaging findings in the initial stage, will be overlooked in low-dose CT. However, considering the amount of radiation dose taken in a short time, it is recommended to prefer low-dose CT in follow-up.

According to the accepted consensus, control CT is recommended between 3-5 days in cases where the initial CT is normal, and 5-7 days in cases with pneumonia findings [14]. Shorter

intervals are recommended in those who have normal initial CT and develop pneumonia rapidly.

Systematic research should be conducted to develop initial descriptive assessments on COVID-19 pneumonia, which creates a huge socioeconomic burden worldwide. Combined big data combining epidemiological, clinical, laboratory and imaging findings will provide improvement in diagnostic criteria and treatment management. Sharing clinical and radiological experiences in different regions will have a positive outcome for this devastating epidemic.

Conflict of interest: The author declares that there is no conflict of interest. The author alone is responsible for the content and writing of the paper.

Financial disclosure: There is no financial support to this study.

References

1. Huang C, Wang Y, Li X, Ren L, Zhao J5, Hu Y, et al. Clinical features of patients infected with 2019 novel coronavirus in Wuhan, China. *Lancet* 2020; 395(10223): 497-506. [[Crossref](#)]
2. World Health Organization (WHO), Geneva, Switzerland. Pneumonia of unknown cause - China, Disease outbreak news, 5 January 2020. Available at: <https://www.who.int/csr/don/05-january-2020-pneumonia-of-unkown-cause-china/en/> [Accessed April 18, 2020].
3. Coronaviridae Study Group of the International Committee on Taxonomy of Viruses. The species Severe acute respiratory syndrome-related coronavirus: classifying 2019-nCoV and naming it SARS-CoV-2. *Nat Microbiol* 2020; 5(4): 536-44. [[Crossref](#)]
4. Salehi S, Abedi A, Balakrishnan S, Gholamrezanezhad A. Coronavirus Disease 2019 (COVID-19): A Systematic Review of Imaging Findings in 919 Patients. *AJR Am J Roentgenol* 2020; 215(1): 87-93. [[Crossref](#)]
5. Huang P, Liu T, Huang L, Liu H, Lei M, Xu W, et al. Use of Chest CT in Combination with Negative RT-PCR Assay for the 2019 Novel Coronavirus but High Clinical Suspicion. *Radiology* 2020; 295(1): 22-3. [[Crossref](#)]
6. Ai T, Yang Z, Hou H, Zhan C, Chen C, Lv W, et al. Correlation of Chest CT and RT-PCR Testing for Coronavirus Disease 2019 (COVID-19) in China: A Report of 1014 Cases. *Radiology* 2020; 296(2): E32-E40. [[Crossref](#)]
7. Xie X, Zhong Z, Zhao W, Zheng C, Wang F, Liu J. Chest CT for Typical Coronavirus Disease 2019 (COVID-19) Pneumonia: Relationship to Negative RT-PCR Testing. *Radiology* 2020; 296(2): E41-E45. [[Crossref](#)]
8. Chung M, Bernheim A, Mei X, Zhang N, Huang M, Zeng X, et al. CT Imaging Features of 2019 Novel Coronavirus (2019-nCoV). *Radiology* 2020; 295(1): 202-7. [[Crossref](#)]
9. Kong W, Agarwal PP. Chest Imaging Appearance of COVID-19 Infection. *Radiol Cardiothorac Imaging* 2020; 2(1): e200028. [[Crossref](#)]
10. Bernheim A, Mei X, Huang M, Yang Y, Fayad ZA, Zhang N, et al. Chest CT Findings in Coronavirus Disease-19 (COVID-19): Relationship to Duration of Infection. *Radiology* 2020; 295(3): 200463. [[Crossref](#)]
11. Pan F, Ye T, Sun P, Gui S, Liang B, Li L, et al. Time Course of Lung Changes at Chest CT during Recovery from Coronavirus Disease 2019 (COVID-19). *Radiology* 2020; 295(3): 715-21. [[Crossref](#)]
12. Ng M-Y, Lee EY, Yang J, Yang F, Li X, Wang H, et al. Imaging Profile of the COVID-19 Infection: Radiologic Findings and Literature Review. *Radiol Cardiothorac Imaging* 2020; 2(1): e200034. [[Crossref](#)]
13. Wang Y, Dong C, Hu Y, Li C, Ren Q, Zhang X, et al. Temporal Changes of CT Findings in 90 Patients with COVID-19 Pneumonia: A Longitudinal Study. *Radiology* 2020; 296(2): E55-64. [[Crossref](#)]
14. Yang Q, Liu Q, Xu H, Lu H, Liu S, Li H. Imaging of coronavirus disease 2019: A Chinese expert consensus statement. *Eur J Radiol* 2020; 127: 109008. [[Crossref](#)].